

Thymoma-associated panencephalitis: a newly emerging paraneoplastic neurologic syndrome

Lynda Adaobi Nwabuobi, Jacob Christian Pellinen, Thomas Mark Wisniewski

Department of Neurology, NYU Langone Medical Center, New York University School of Medicine, New York, NY 10016, USA.

Correspondence to: Dr. Lynda Adaobi Nwabuobi, Department of Neurology, NYU Langone Medical Center, New York University School of Medicine, 550 1st Avenue, New York, NY 10016, USA. E-mail: lynda.nwabuobi@med.nyu.edu

How to cite this article: Nwabuobi LA, Pellinen JC, Wisniewski TM. Thymoma-associated panencephalitis: a newly emerging paraneoplastic neurologic syndrome. *Neuroimmunol Neuroinflammation* 2017;4:117-23.



Dr. Lynda Adaobi Nwabuobi is an adult neurology resident at NYU School of Medicine. Her clinical interests include Parkinson's disease, neurological autoimmune and paraneoplastic syndromes, global health and health care disparities. She plans to pursue a fellowship in Movement Disorders. At the age of 12, she emigrated from Nigeria with her family and currently resides in New York. She enjoys visiting art museums, fine dining and spending time with her family.

Article history:

Received: 29-11-2016
Accepted: 22-03-2017
Published: 16-06-2017

Key words:

Immunology,
autoimmune diseases,
encephalitis,
thymoma,
paraneoplastic syndrome

ABSTRACT

Recently, a few case reports of thymoma-associated panencephalitis (TAPE) have brought to light a disease entity that has not been fully characterized. Literature review of TAPE reveals an array of associated neuronal antibodies, with varied responses to thymectomy with or without immunotherapy. This report describes a case of TAPE and proposes that the GABA_A receptor antibody is a potential target antigen driving the immune process in this disease entity. Treatment-wise, early thymectomy consistently improves the overall course of disease. Further study of such cases will be critical in clarifying the mechanisms of disease, improving early diagnosis, and developing targeted approaches to treatment.

INTRODUCTION

Thymomas are often associated with paraneoplastic neurologic syndromes (PNS) as they have the propensity to express different autoantibodies against

neuronal antigens, many of which clinical pathogenicity have not been established.^[1,2] Quite rarely, thymomas have been associated with limbic encephalitis, a well-characterized neurological syndrome that presents with memory impairment, behavioral changes, and



This is an open access article distributed under the terms of the Creative Commons Attribution-NonCommercial-ShareAlike 3.0 License, which allows others to remix, tweak, and build upon the work non-commercially, as long as the author is credited and the new creations are licensed under the identical terms.

For reprints contact: service@oaepublish.com

Quick Response Code:



seizures.^[3] The target antigen when it manifests in thymomas is largely unknown, however, some cases have reported antibodies to α -amino-3-hydroxy-5-methylisoxazole-4-propionic acid receptor, leucine-rich glioma inactivated 1 protein (LGI1), contactin associated protein 2 (Caspr2), and glutamic acid decarboxylase (GAD).^[4] A new entity has been described in a few cases of paraneoplastic encephalitis associated with thymomas, with lesions extending beyond the mesial temporal lobe structures.

CASE REPORT

A 35-year-old man presented with a 2-week history of seizures, poor appetite, generalized headaches and nausea. Neurologic assessment revealed poor attention, orientation and memory loss, without clinical seizures. Computed tomography head showed multiple cortical hypodensities, prompting an magnetic resonance imaging (MRI) brain, which revealed multiple foci of cortical hyperintensity involving the medial left frontal cortex, the right dorsal aspect of the insula and adjacent right temporal cortex as well as the posterior left temporal cortical medullary junction and the medial posterior left temporal cortex and lateral cortex [Figure 1]. Electroencephalogram revealed

hyperexcitability over the right temporal region and frequent focal seizures and he was empirically treated with IV acyclovir, lacosamide and levetiracetam. Cerebral spinal fluid (CSF) analysis revealed protein of 0.51 g/L, glucose of 3.5 mmol/L, 3×10^6 /L red blood cells and 9×10^6 /L white blood cells (76% lymphocytes, 18% monocytes, 6% neutrophils). CSF and serum studies were also positive for neuronal antibodies to GAD [3.93 nmol/L in the CSF (normal < 0.02 nmol/L), > 250.0 kIU/L in the serum (reference range 0-5 kIU/L)], VGKC-complex antibodies [159 pmol/L in the CSF (reference range 0-31 pmol/L), 98 pmol/L in the serum (reference range 0-31 pmol/L)], CRMP5 (reflex titer < 1:240; positive western blot), and AchR [binding antibody 17.5 nmol/L in the CSF (normal < 0.02 nmol/L), and 142.8 nmol/L in the serum (reference range 0.0-0.4 nmol/L)]. Additionally, serum studies revealed presence of systemic antibodies to thyroperoxidase (37.8 kIU/L, reference range 0-5.5 kIU/L), thyroglobulin (372.2 kIU/L, reference range 0-5 kIU/L), Ro/SSA (6.8 AI, reference range < 1 AI), and an ANA titer of 80 (reference range 0-40) with a nucleolar pattern. A paraneoplastic syndrome was suspected, and full body imaging revealed a large multilobulated right anterior mediastinal mass, interfacing multiple right-sided mediastinal structures and invading the

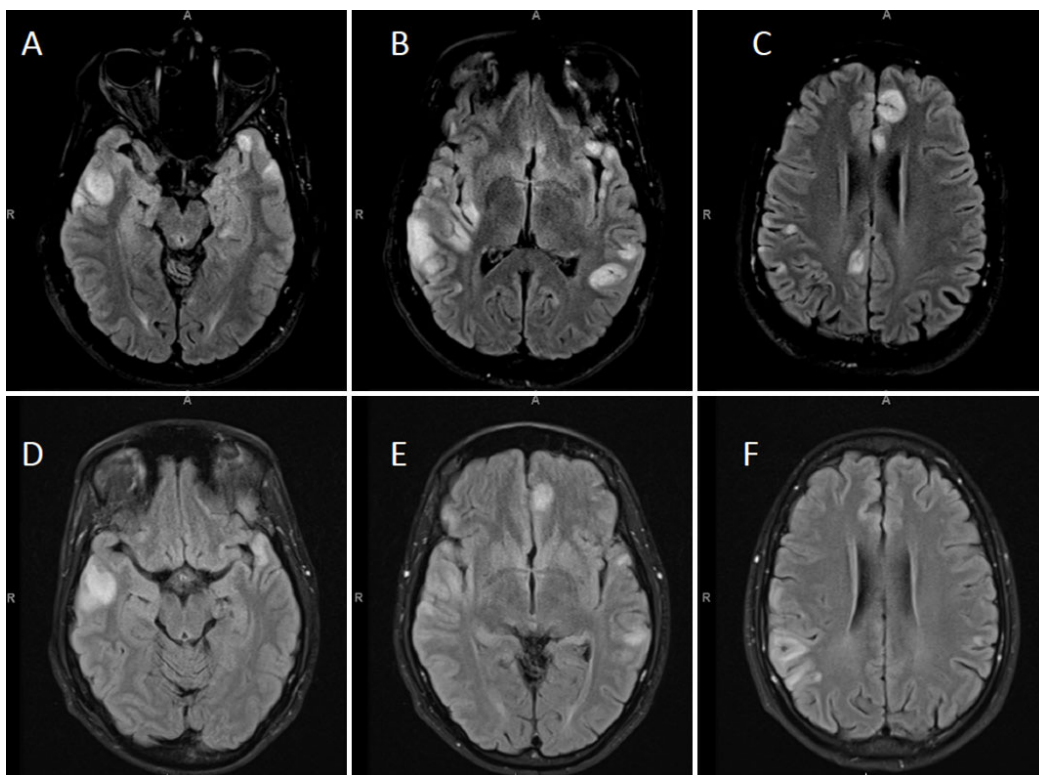


Figure 1: Initial and follow-up magnetic resonance imaging brain scans showing multiple cortically-based signal abnormalities. Images A-C are axial fluid-attenuated inversion recovery images showing multifocal elevated cortical T2/FLAIR signal intensity with associated swelling with involvement of the adjacent subcortical white matter from patient's initial presentation. There was no contrast enhancement, and there was no definite involvement of the deep gray structures, brainstem, or cerebellum. Images D-F are follow up images approximately two weeks later that reveal overall improvement, for instance, previously seen abnormality along the medial left frontal lobe, and in the posterior right insular lesion improved

bilateral lung apices. This mass was later confirmed to be a metastatic type B2, stage III thymoma via biopsy and after resection [Figure 2]. The patient was treated with intravenous methylprednisolone (1 g/day for 10 days) followed by 0.4 g/kg daily immunoglobulin (IVIG) for total of 4 days. He had significant improvement in his mental status with the first dose of steroids. Repeat imaging 2 weeks after initial presentation showed improvement in the cortical lesions, specifically, decrease in the abnormal fluid-attenuated inversion recovery (FLAIR) hyperintensities [Figure 1]. Further treatment included chemotherapy with cisplatin, doxorubicin, and cyclophosphamide given the invasive nature of the thymoma. Prior to thymectomy, his course was complicated by gastrointestinal dysmotility syndrome thought to be a result of his paraneoplastic syndrome. He underwent a successful thymectomy with complete resection approximately 3 months after initial presentation, and continued to improve thereafter.

DISCUSSION

Based on literature review, our patient is one of the very few reported cases of thymoma-associated panencephalitis (TAPE). These cases highlight the similar neurological symptoms at presentation -- seizures, confusion, and memory loss being the most common -- with a constellation of positive antibodies and different responses to treatment [Table 1]. The similar presentations and MRI findings in these patients support TAPE as a distinct disease entity and autoimmune disorder. Our case was unique as our patient was found to have multiple neuronal and non-neuronal antibody responses and had a

drastic improvement in his clinical symptoms with just immunotherapy, unlike other cases that showed improvement after thymectomy and/or extensive immunotherapy. In order to further characterize TAPE as a paraneoplastic syndrome, antibody associations need to be elicited.

In reviewing the prior reported cases, these patients can have a variety of autoantibodies as seen in Table 1, the most common being AchR, present in 9 of 16 cases, with 5 having symptoms of myasthenia gravis (MG). This is not surprising as up to 37% of patients with thymic tumors but without MG have been reported to have positive antibody titers to AchR.^[5] Voltage-gated potassium channel (VGKC) was the 2nd most common antibody seen in 5 patients. It has been proven that the antibodies to VGKC actually target the associated proteins LGI1 and Caspr2, and not the channel itself, therefore rendering the term, "antibodies to VGKC" obsolete.^[6] Antibodies to LGI1 and Caspr2 were present in 3 and 1 of the patients, respectively. Both CRMP-5 and GAD were occasionally present among the cases. The presence of GAD antibodies in thymoma is associated with stiff person syndrome and unlikely to manifest as encephalitis.^[1] CRMP-5 has been shown to be a marker of immune response initiated by thymomas in different PNS, and therefore, may not be neuropathogenic.^[7] Antibodies against Hu, Ri, and Yo were the least common, absent in 50% of the patients. Review of associated antibodies in these previously reported cases does not show a clear pattern, and it is unclear which antibodies are actually pathologic and which ones are incidental. Of significant importance, Petit-Pedrol *et al.*^[8] recently reported 6 patients who presented very similarly to

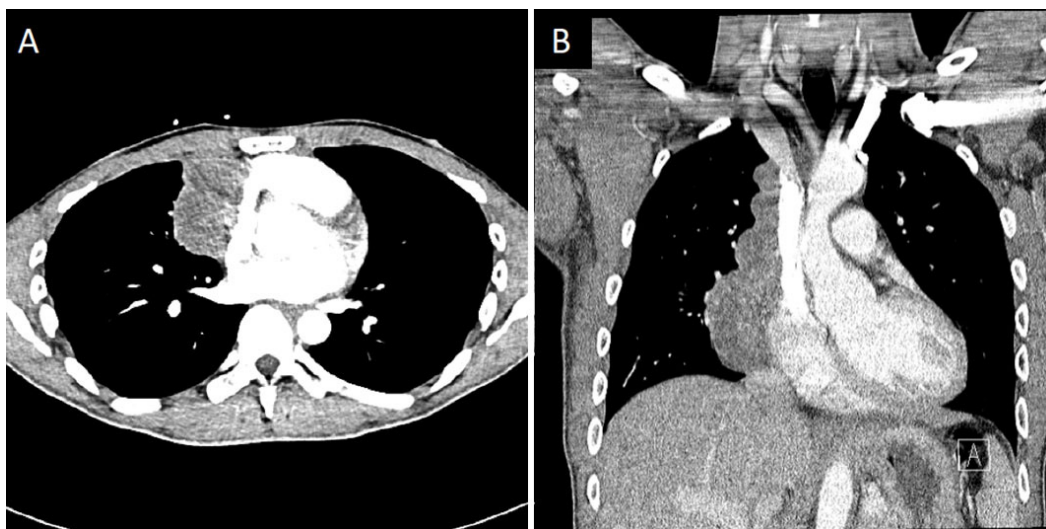


Figure 2: Computed tomography chest showing large right mediastinal mass. Contrast-enhanced computed tomography images (A: axial; B: coronal), showing a large multilobulated right anterior mediastinal mass measuring 6.0 cm × 4.7 cm in transverse dimension by approximately 13 cm in craniocaudal dimension. There was found to be mass effect with mild compression of the right atrium and superior vena cava (though patent). Thymoma was suspected, and proven later on biopsy

Table 1: Literature review of cases of thymoma-associated panencephalitis

Paper	Year	Age	Gender	Neurological symptoms	Antibodies (+)	Antibodies (-)	Cell surface vs. onconeural Ab	Treatment	Improvement
This case		35	M	Seizures, confusion, agitation, decreased to no verbal response	GAD, VGKC-complex, AchR (binding), CRMP5	Hu, Ri, Yo, VGCC, NMDA, GABA-B, AMPA, ANNA-3, anti-glial nuclear, PCA-2, PCA-Tr, amphiphysin, AchR (ganglionic neuronal)	Cell surface/onconeural	Steroids, IVIG, chemotherapy, thymomectomy	1 day after steroids
Reginold et al. ^[11]	2016	47	M	Psychosis, seizures, ocular weakness	-	Hu, Ri, Yo	-	Steroids, thymomectomy	Over 4 weeks after steroids and thymomectomy
Simabukuro et al. ^[12]	2015	45	F	MG; 8 years later, memory loss, behavioral changes	GABA-A, LGI1, AchR	GABA-B, AMPA, NMDA, Caspr2, GlyR, mGluR5, mGluR1, GAD	Cell surface	Steroids, PLEX, thymomectomy	Improved after initial treatment, with recurrence 3 months later and improvement after removal of thymic met
Aragaki et al. ^[13]	2015	66	F	Leg cramping/inability to walk, seizures	-	AchR	-	Thymomectomy	6 days after thymomectomy and doing fairly well 7 months later
Aysal et al. ^[14]	2013	43	M	Seizures, MG (bulbar symptoms)	AchR	VGKC-complex	Cell surface	IVIG, pyridostigmine	MG symptoms improved after IVIG, then seizures improved after thymomectomy; MRI normal 2 years later and patient doing well
Suh et al. ^[15]	2013	42	F	Memory loss, voice change, ptosis, agitation, drowsiness	AchR	Hu, Ri, Yo	Cell surface	Thymomectomy	Improvement in mental status 10 days after thymomectomy and almost complete recovery 3 months later; asymptomatic 2 years later
Miyazaki et al. ^[16]	2012	46	M	MG; 4 years later, aphasia, seizures, delirium, visual hallucinations	AchR, GABA-A, LGI1	-	Cell surface	Thymomectomy, steroids, IVIG	Status epilepticus resolved 2 weeks after treatment, but cognitive impairment and psychological symptoms remained
Erkmen et al. ^[17]	2011	61	F	Seizures	LGI1	-	Cell surface	IVIG, steroids, thymomectomy	Over 4 weeks prior to thymomectomy
Werry et al. ^[18]	2009	32	M	Vertigo, diplopia, nystagmus, left hand clumsiness, gait disturbances, gait ataxia, myoclonic jerking, memory loss, hallucinations, anxiety; 1yr later, MG.	CRMP5; later AchR	VGKC-complex, Hu, Ri, Yo, Ma-2, amphiphysin	Cell surface/onconeural	Thymomectomy, steroids, IVIG, PLEX	No improvement after thymomectomy, steroids, IVIG, and partial PLEX until 4 months later; 1 year later, developed MG, which completely resolved with immunosuppression

Continued...

Paper	Year	Age	Gender	Neurological symptoms	Antibodies (+)	Antibodies (-)	Cell surface vs. onconeural Ab	Treatment	Improvement
Rizzardi et al. ^[19]	2009	55	F	Seizures, aphasia	-	AchR, Hu, Ri, Yo	-	Thymomectomy	Total remission of symptoms 1 week after thymomectomy
Hammoud et al. ^[20]	2009	43	F	MG; 4yrs later, seizure, confusion, aphasia	AchR (binding, modulating), striational Ab, VGKC-complex	"Rest of paraneoplastic profile, including CRMP-5"	Cell surface	Steroids, IVIG, 1 cycle of chemotherapy	Some improvement of speech and cognitive function, but died 2 months later from mets
Okita et al. ^[21]	2007	33	F	Seizure; later, incontinence, confusion, decreased verbal response, apallial syndrome, RLE weakness; later, decreased consciousness and apallial syndrome	AchR	Hu, Ri, Yo, CRMP5, Ma-2, Tr, amphiphysin, VGKC-complex	Cell surface	Thymomectomy, steroids	Had thymomectomy several years prior to 3 separate presentations with ELE, 1 of which did not require treatment; the other 2 responded fairly well to steroids
Ohshita et al. ^[22]	2006	59	F	Memory impairment, apathy	GABA-A, Caspr2	AchR, Hu, Yo	Cell surface	Thymomectomy, chemotherapy	Improved initially with no treatment, but with recurrence, partial improvement of mental status 2 months after chemo
Ances et al. ^[23]	2005	38	M	Seizure, confusion, agitation; later, spasms and rigidity	GAD, neuropil of hippocampus	VGKC-complex	Onconeural	Thymomectomy, radiation therapy, steroids, IVIG, PLEX	Within 3 weeks after thymomectomy, radiation and steroid; developed spasms and rigidity after prednisone taper, not responsive to PLEX or IVIG, but improved with steroids only
Vermino et al. ^[24]	2002	34	F	Vertigo, tinnitus, vomiting; later, leg weakness and numbness, tingling of toes and fingers, R visual disturbance, R facial twitching, aphasia	Hu, VGKC-complex	AchR	Cell surface/ onconeural	Thymomectomy	Improved after thymomectomy
Rickman et al. ^[25]	2000	55	M	Dysarthria, seizure, confusion, short term memory impairment, word finding difficulty; later, unsteady gait, limb ataxia, expressive aphasia	AchR (binding, modulating), striational Ab, CRMP5	Hu, Ri, Yo, PCA-2, amphiphysin, VGKC-complex, VGCC, neuronal AchR	Cell surface/ onconeural	Thymomectomy, steroids, PLEX	Worsened after thymomectomy, with no response to steroids, but responded to PLEX; however, suddenly deteriorated later and died

GAD: glutamic acid decarboxylase; VGKC: voltage gated potassium channel; AchR: acetylcholine receptor; CRMP-5: collapsing response mediator protein 5; VGCC: voltage gated calcium channel; NMDAR: N-methyl-D-aspartate receptor; GABA-A-R: gamma-amino-butyric acid type A receptor; GABA-B-R: gamma-amino-butyric acid type B receptor; AMPAR: α-amino-3-hydroxy-5-methylisoxazole-4-propionic acid receptor; LGI1: leucine-rich, glioma inactivated 1; Caspr2: contactin associated protein 2; GlyR: glycine receptor; mGLUR5: metabotropic glutamate receptor 5; mGLUR1: metabotropic glutamate receptor 1; ANNA-3: anti-neuronal nuclear antibody 3; PCA-1, 2, Tr: purkinje cell antibody 1, 2, Tr; PLEX: plasmapheresis; IVIG: immunoglobulin; ELE: extralimbic encephalitis; MG: myasthenia gravis

our patient (behavioral/cognitive changes, seizures, multifocal T2/FLAIR lesions) with high titer CSF and serum antibodies to GABA_AR. These patients did not have evidence of thymoma, however, did have other evidence of immune dysregulation, including the presence of other antibodies.^[8] Most importantly, the GABA_AR antibody was shown to have pathogenic effects on the antigen, specifically, downregulation of receptors in cultured neurons and patients usually responded to therapy.^[8,9] Furthermore, Ohkawa *et al.*^[9] retested the sera of 2 patients previously with TAPE via a nonbiased proteomic method and identified antibodies to GABA_AR. Our patient was not tested for this antibody, however, his clinical findings, brain imaging, and response to therapy are suggestive of GABA_AR associated paranecephalitis.

One of the setbacks in managing TAPE is early recognition as there are so few cases reported. PNS associated with antineuronal cell surface antibodies are often highly responsive to treatment, while those with onconeurological antibodies have a generally poor response.^[10] Review of the cases shows responses to treatments differed without any clear correlation to antibody types. Every patient received thymectomy with partial or full response followed by a combination of steroids, plasmapheresis and/or IVIG. This suggests that early surgical removal of tumors with or without immunotherapy could provide a good chance of recovery from disease. Albeit, the presence of both cell-surface and onconeurological antibodies in our patient may indicate a poor prognosis despite his initial rapid improvement.

Authors' contributions

Concept, literature search, preparation, editing and revision of manuscript: L. Nwabuobi
Patient data and imaging acquisition, editing and revision of manuscript: J. Pellinen
Supervision and revision of manuscript: T. Wisniewski

Financial support and sponsorship

None.

Conflicts of interest

There are no conflicts of interest.

Patient consent

Verbal consent was obtained from the patient.

Ethics approval

Not applicable.

REFERENCES

- Marx A, Willcox N, Leite MI, Chuang WY, Schalke B, Nix W, Strobel P. Thymoma and paraneoplastic myasthenia gravis. *Autoimmunity* 2010;43:413-27.
- Kondo K, Yoshizawa K, Tsuyuguchi M, Kimura S, Sumitomo M, Morita J, Miyoshi T, Sakiyama S, Mukai K, Monden Y. WHO histologic classification is a prognostic indicator in thymoma. *Ann Thorac Surg* 2004;77:1183-8.
- Evoli A, Lancaster E. Paraneoplastic disorders in thymoma patients. *J Thorac Oncol* 2014;9:S143-7.
- Graus F, Titulaer MJ, Balu R, Benseler S, Bien CG, Cellucci T, Cortese I, Dale RC, Gelfand JM, Geschwind M, Glaser CA, Honnorat J, Hofberger R, Iizuka T, Irani SR, Lancaster E, Leypoldt F, Pruss H, Rae-Grant A, Reindl M, Rosenfeld MR, Rostasy K, Saiz A, Venkatesan A, Vincent A, Wandinger KP, Waters P, Dalmau J. A clinical approach to diagnosis of autoimmune encephalitis. *Lancet Neurol* 2016;15:391-404.
- Ohta M, Itoh M, Hara H, Itoh N, Nishitani H, Hayashi K, Ohta K. Anti-skeletal muscle and anti-acetylcholine receptor antibodies in patients with thymoma without myasthenia gravis: relation to the onset of myasthenia gravis. *Clin Chim Acta* 1991;201:201-5.
- Lai M, Huijbers MG, Lancaster E, Graus F, Bataller L, Balice-Gordon R, Cowell JK, Dalmau J. Investigation of LGI1 as the antigen in limbic encephalitis previously attributed to potassium channels: a case series. *Lancet Neurol* 2010;9:776-85.
- Yu Z, Kryzer TJ, Griesmann GE, Kim K, Benarroch EE, Lennon VA. CRMP-5 neuronal antibody: marker of lung cancer and thymoma-related autoimmunity. *Ann Neurol* 2001;49:146-54.
- Petit-Pedrol M, Armangue T, Peng X, Bataller L, Cellucci T, Davis R, McCracken L, Martinez-Hernandez E, Mason WP, Kruer MC, Ritacco DG, Grisold W, Meaney BF, Alcalá C, Silveira-Smith P, Titulaer MJ, Balice-Gordon R, Graus F, Dalmau J. Encephalitis with refractory seizures, status epilepticus, and antibodies to the GABA_A receptor: a case series, characterisation of the antigen, and analysis of the effects of the antibodies. *Lancet Neurol* 2014;13:276-86.
- Ohkawa T, Satake S, Yokoi N, Miyazaki Y, Ohshita T, Sobue G, Takashima H, Watanabe O, Fukata Y, Fukata M. Identification and characterization of GABA_A receptor autoantibodies in autoimmune encephalitis. *J Neurosci* 2014;34:8151-63.
- Hofberger R, Rosenfeld MR, Dalmau J. Update on neurological paraneoplastic syndromes. *Curr Opin Oncol* 2015;27:489-95.
- Reginold W, Ninan K, Coret-Simon J, Haider E. Paraneoplastic limbic and extra-limbic encephalitis secondary to a thymoma mimicking an acute stroke. *Can J Neurol Sci* 2016;43:420-3.
- Simabukuro MM, Petit-Pedrol M, Castro LH, Nitrini R, Lucato L, Zambon AA, Silva, LG, Fortes GC, Soares Neto HR, Dalmau JO. GABA_A receptor and LGI1 antibody encephalitis in a patient with thymoma. *Neurol Neuroimmunol Neuroinflamm* 2015;2:e73.
- Aragaki M, Iimura Y, Teramoto K, Sato N, Hirose K, Hasegawa N. Paraneoplastic extralimbic encephalitis associated with thymoma: a case report. *Ann Thorac Cardiovasc Surg* 2015;21:300-402.
- Aysal F, Baybas S, Selcuk HH, Sozmen V, Ozturk M, Kucukoglu H, Urer NH. Paraneoplastic extralimbic encephalitis associated with thymoma and myasthenia gravis: three years follow up. *Clin Neurol Neurosurg* 2013;115:628-31.
- Suh JW, Haam SJ, Song SW, Shin YR, Paik HC, Lee DY. Paraneoplastic encephalitis associated with thymoma: a case report. *Korean J Thorac Cardiovasc Surg* 2013;46:234-6.
- Miyazaki Y, Hirayama M, Watanabe H, Usami N, Yokoi K, Watanabe O, Sobue G. Paraneoplastic encephalitis associated with myasthenia gravis and malignant thymoma. *J Clin Neurosci* 2012;19:336-8.
- Erkmen CP, Fadul CE, Dalmau J, Erkmen K. Thymoma-associated paraneoplastic encephalitis (TAPE): diagnosis and treatment of a potentially fatal condition. *J Thorac Cardiovasc Surg* 2011;141:17-20.
- Werry C, Gotz F, Wurster U, Stangel M, Giess R, Heidenreich F,

- Windhagen A. Paraneoplastic autoimmune encephalitis associated with CV2/CRMP-5 IgG antineuronal antibodies in a patient with thymoma. *J Neurol* 2009;256:129-31.
19. Rizzardi G, Campione A, Scanagatta P, Terzi A. Paraneoplastic extra limbic encephalitis associated with thymoma. *Interact Cardiovasc Thorac Surg* 2009;9:755-6.
 20. Hammoud K, Kandimala G, Warnack W, Vernino S. Multifocal paraneoplastic cortical encephalitis associated with myasthenia gravis and thymoma. *Arch Neurol* 2009;66:1407-9.
 21. Okita K, Matsukawa N, Hattori M, Yamada K, Takada K, Yamawaki T, Yoshida M, Hashizume Y, Ojika K. Recurrent limbic and extralimbic encephalitis associated with thymoma. *Clin Neurol Neurosurg* 2007;109:206-9.
 22. Ohshita T, Kawakami H, Maruyama H, Kohriyama T, Arimura K, Matsumoto M. Voltage-gated potassium channel antibodies associated limbic encephalitis in a patient with invasive thymoma. *J Neurol Sci* 2006;250:167-9.
 23. Ances BM, Vitaliani R, Taylor RA, Liebeskind DS, Voloschin A, Houghton DJ, Galetta SL, Dichter M, Alavi A, Rosenfeld MR, Dalmau J. Treatment-responsive limbic encephalitis identified by neuropil antibodies: MRI and PET correlates. *Brain* 2005;128:1764-77.
 24. Vernino S, Eggengerger ER, Rogers LR, Lennon VA. Paraneoplastic neurological autoimmunity associated with ANNA-1 autoantibody and thymoma. *Neurology* 2002;59:929-32.
 25. Rickman OB, Parisi JE, Yu Z, Lennon VA, Vernino S. Fulminant autoimmune cortical encephalitis associated with thymoma treated with plasma exchange. *Mayo Clin Proc* 2000;75:1321-6.